

Print ISSN: 2320-6071  
Online ISSN: 2320-6012  
www.msjonline.org

# IJRMS

International Journal of

Research in Medical Sciences

ISSN 2320-6071 (Print) / ISSN 2320-6012 (Online) / www.msjonline.org

Volume 7, No 3 (March 2019)

## Original Research Article

# Breast state improvement by using the lymphatic drainage disposable bra pads

Edvard V. Kryzhanovskii<sup>1\*</sup>, Alexander B. Yavorsky<sup>2</sup>, Lim Kwong Choong<sup>3</sup>,  
Muslim Liew Bin Abdullah<sup>4</sup>

<sup>1</sup>Telebiomet, SIE of Moscow Technical University of Communications and Informatics, Saint-Petersburg, Russia

<sup>2</sup>Sports Medicine Clinics, Russian State University of Physical Education, Sport, Youth and Tourism, Moscow, Russia

<sup>3</sup>BAE International Inc. SDN BHD, Kuala-Lumpur, Malaysia

<sup>4</sup>BAE Trading SDN BHD, Kuala-Lumpur, Malaysia

**Received:** 19 December 2018

**Accepted:** 29 January 2019

### \*Correspondence:

Dr. Edvard V. Kryzhanovskii,

E-mail: [edward@telebiomet.ru](mailto:edward@telebiomet.ru)

**Copyright:** © the author(s), publisher and licensee Medip Academy. This is an open-access article distributed under the terms of the Creative Commons Attribution Non-Commercial License, which permits unrestricted non-commercial use, distribution, and reproduction in any medium, provided the original work is properly cited.

## ABSTRACT

**Background:** The health and good esthetic conditions of the breast are important indicators of women's life quality. One factor that negatively affects this quality is the breast ptosis, associated with the sagging of the mammary glands due to tissue stretching and the loss of tissue and skin elasticity. New tools and methods able to improve the shape and beautiful contour of the breast are highly desirable.

**Methods:** We investigated how the disposable bra pads by BAE International Inc., having the lymphatic drainage effect for the breast, influenced the female breast state. We applied two methods, the ultrasound elasticity imaging and the pattern recognition of the nipples position, to monitor the breast state dynamics in two groups of females, the study and control ones.

**Results:** Preliminary results showed that both the breast elasticity and the pattern of nipple positions improved for females wearing the bra pads as compared to females wearing regular bras without pads ( $P < 0.05$  for the difference between the two groups of females).

**Conclusions:** Overall, the bra pads by BAE can be considered as an effective tool encouraging metabolism by improving the flow of blood circulation and lymph in the breast.

**Keywords:** Bra pads by BAE, Breast elasticity, Breast health, Breast ptosis, Lymphatic drainage, Nipples position

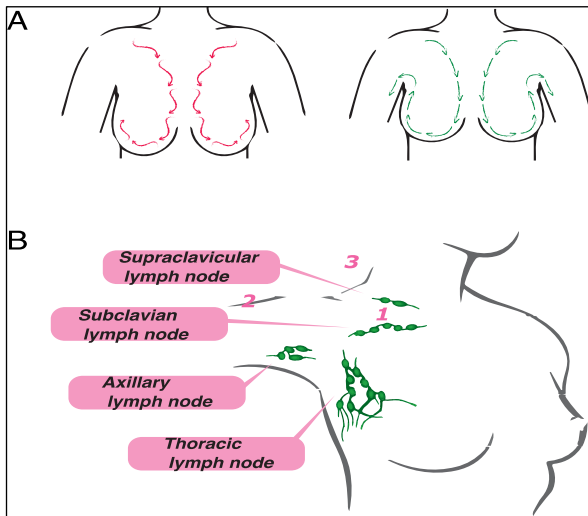
## INTRODUCTION

The current medical knowledge allows of monitoring many parameters of the breast condition and health.<sup>1-8</sup> These conditions are also related to the aesthetic aspects of the bust. The breast tissue consists mainly of fat and mammary gland, the basis of which is the large pectoral muscle and the surface is supported by the skin. The aesthetic assessment of the breasts depends not only on the size, but also on the skin firmness. As a consequence,

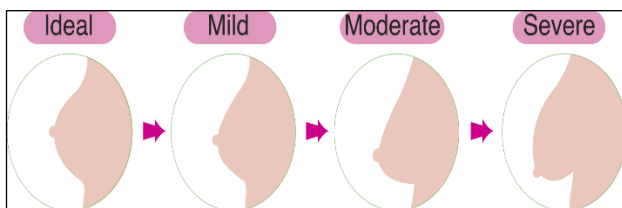
various cosmetological procedures are used combining bust-up and skin beautification concurrently. For the procedures to be effective, it is important to encourage metabolism by improving the flow of blood circulation and lymph (Figure 1).

One common problem is the breast ptosis (Figure 2), which is the sagging of the mammary glands occurring as a result of tissue stretching and the loss of tissue and skin

elasticity. Ptosis disrupts the shape and beautiful contour of the breast.<sup>2-3</sup>



**Figure 1: A) Illustration of a bad (left) and a good (right) flow patterns in the breast. B) Important lymph nodes. Points 1-3 are associated with the key steps necessary to prevent breast ptosis (see the text).**



**Figure 2: Stages of the breast ptosis.**

Ptosis can develop as a result of pregnancy, when the breast first significantly increases in size and then decreases after feeding is completed, and the cutaneous tissues can no longer be reduced to the original level. Sharp weight loss can also increase breast ptosis. Another factor contributing to the sagging is due to the age-related changes, when the breast tissue gradually atrophies and decreases in volume, while the size of the skin pocket remains the same.

At the physiological level, breast ptosis is a consequence of the following underlying causes:

- Clogging of thoracic lymph nodes;
- Great pectoral muscle and pectoral muscle weakened;
- Growth of “Cooper ligament” hanging bust;
- Degradation of tension due to the decline of the developed mammary gland.

To prevent breast ptosis, the following steps are necessary: improve lymph node flow, improve blood flow, and strengthen muscular strength of pectoral muscle (points 1, 2, and 3, respectively, in Figure 1B).

We investigated the effect exerted by specific bra pads on the breast state in a group of female volunteers. The lymphatic drainage disposable bra pads manufactured by BAE International Inc. were used in the study.<sup>9</sup> These pads are inserted into the bra and can be worn by a woman on a daily basis, with two pieces per day. According to the parameters stated by the manufacturer, the pads promote blood circulation, lift and firm the breasts, and optimize human bio-energy. Therefore, the bra pads under study has a potential for preventing conditions leading to ptosis and related breast problems.

## METHODS

### Bra pads

The bra pads manufactured by BAE International Inc. and used in the study are shown in Figure 3. The pads are made of 100% cotton with an extra thin design. The pads are disposable and should be replaced each day. Two pads are placed inside the bra during the day and stuck on the night T-shirt during the sleeping time. The pad material contains a double adhesive tape preventing sliding. Before the start of the experiment, the volunteers confirmed the subjective assessment of the pad material as soft and breathable.



**Figure 3: The bra pads used in the study are shown wrapped (left) and unwrapped (right).**

According to the manufacturer, the bra pads provide the following effects:

- Negative ion effect: Improve the flow of lymph, carries away the waste material of bust flow, let the female hormone spread out.
- Far infrared effect: Activate the subcutaneous cells and warm from inside.
- Antimicrobial and deodorant effect: Suppresses smell and clean.
- Surfactant effect: Dirt resistant, always refreshing.
- Myocyte activation effect: Tightening by activation of muscle cells.
- Weak magnetic field effect: Adjust blood pressure, autonomic nerve.

## Volunteers

Two groups of female volunteers with an age range of 20 to 50 years participated in the experiment. The first group was the study group involving 15 volunteers who were wearing the bra pads by BAE on a daily basis for 2 months. The second group was the control group involving other 15 volunteers who were wearing regular bras without the pads for the same 2 months.

The initial breast state (background state) of volunteers from the both groups was estimated by the ultrasound elasticity imaging and by pattern recognition of the nipples position. After two months of the experiment, the same diagnostic approaches were conducted again for volunteers from the study and control groups, and the differences between the initial and final states and between the study and control groups were statistically evaluated.

## Breast state diagnostic methods

The first diagnostic method used to assess the breast state of the volunteers was the ultrasound elasticity imaging.<sup>10</sup> This method estimates tissue hardness by means of ultrasound wave radiation of a subject under study and imaging its response to various modifications. It can be viewed as an advanced extension of palpation and earlier ultrasound approaches including echopalpation. Measurements result in images showing strain in response to external force or estimated elastic modulus. Based on these images, objective information can be obtained about tissue stiffness and/or elasticity.

We chose the ultrasound elastography as a diagnostic method in our study by several reasons. First of all, approach is currently the most common method of elasticity imaging. Moreover, some previous studies already demonstrated that breast mass elastography is very promising, for example, in mammography for cancer detection.<sup>11-15</sup>

The ultrasound elasticity estimation was conducted for each volunteer in each of the two group before and after the start of the experiment. Both breasts of a volunteer were evaluated during the diagnostic procedure. Elastograms were obtained showing response of the breasts to a series of manual compression of the breasts. For each patient, visual comparison of her elastograms from the start and from the end of the experiment was performed and the change in breast elasticity was estimated according to the following three possible values for each breast: “no change,” “elasticity decreased,” or “elasticity increased.”

The second diagnostic method used to assess the breast state of the volunteers was the pattern recognition of the nipples position. Each volunteer was set to the fixed place and leaned against a wall in a fixed position in the measurement room, and a photo shot of the volunteer

with a bare chest was taken. The fixation was individual for each volunteer and was assured by controlling the 2D spatial positions (on the wall) of several reference points along the body profile, including positions of shoulders, the tip of the head, and the armpits. Before taking the photo shot at the end of the experiment, we made certain that the volunteer fits into the spatial positions of her reference points recorded at the start of the experiment. The two-dimensional coordinates of the breast nipples of each volunteer were extracted from the photos taken at the start and at the end of the experiment. These measurements were processed to calculate the vertical change (in cm) in the nipples position resulted from the experiment.

## Statistical evaluation

Depending on the sample distributions, the statistical analysis was performed using the parametric Student and Fisher tests or the non-parametric Wilcoxon and Kolmogorov-Smirnov tests, evaluated in the Statistica 10.0 software.

## RESULTS

Female volunteers from the study group were wearing the bra pads by BAE International Inc. for 2 months, while volunteers from the control group used regular bras without any modifications for the same period. After the experiment, the general psychological state of the volunteers was assessed. Emotional evolution of volunteers from both groups after this time period was quite diverse and hardly distinguishable between the groups, probably because of personal circumstances which was hard to control and, thus, which were not included in the analysis.

A more stringent emotional indicator is a general subjective estimate for the feeling of satisfaction by the bra pads. We evaluated the emotional reaction of volunteers from the study group to the pads by thoroughly interviewing each such volunteer. 14 of 15 women expressed definite satisfaction with the bra pads (the average quantitative index of satisfaction was  $8.5 \pm 0.5$  on the scale in which 10 was the maximal satisfaction), and 1 volunteer reported neutral reaction to the pads. No volunteers from the study group reported any complaints about quality of the bra pads or any discomfort during the process of wearing.

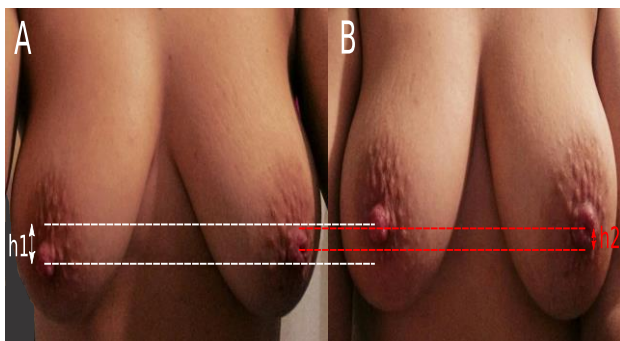
The analysis of elastograms of the breast tissues revealed a statistically significant ( $P < 0,05$ ) increase in breast elasticity for volunteers from the study group after the two months of the experiment (Table 1). 12 patients in the study group exhibited definite patterns of positive change in breast elasticity visible in the ultrasound images. On the contrary, we could not find solid evidence for any changes (neither positive nor negative) in breast elasticity for females from the control group (Table 1).

**Table 1: Estimates of breast elasticity in the two groups of female volunteers, based on the analysis of breast elastograms at the start and at the end of the experiment.**

	Number of female volunteers		
	No change	Elasticity decreased	Elasticity increased
Study group	2	1	12
Control group	8	4	3

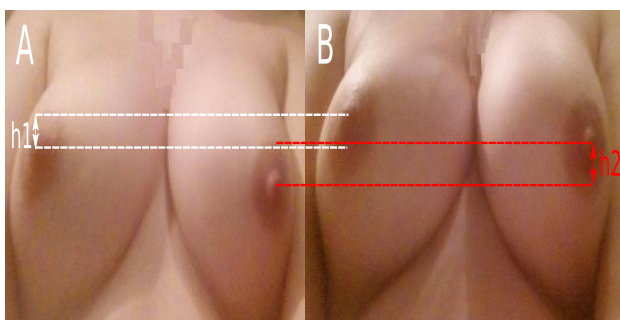
The computational analysis of the nipples position revealed a statistically significant ( $P < 0.05$ ) vertical increment in coordinates of both nipples for volunteers from the study group after the two months of the experiment: average vertical increment =  $0.7 \pm 0.3$ cm. There was no significant change in the nipples positions (in the vertical direction) for volunteers from the control group: average vertical increment =  $0.0 \pm 0.2$ cm.

The changes in the breast state of two volunteers randomly picked from the study group can be visually estimated in Figures 4 and 5.



The vertical shift of the left breast nipple is  $h_1 = 1.4$ cm, and for the right breast nipple  $h_2 = 1.0$ cm.

**Figure 4: Example of the breast states of a volunteer from the study group (A) before and (B) after the experiment.**



The vertical shift of the left breast nipple is  $h_1 = 0.7$ cm, and for the right breast nipple  $h_2 = 0.9$ cm.

**Figure 5: Example of the breast states of a volunteer from the study group (A) before and (B) after the experiment.**

## DISCUSSION

Esthetic beauty of the bust is an important subjective factor in lives of many women. As a consequence, the market of facilities enhancing this beauty is constantly growing. However, it is not always possible to objectively measure the real effect that these facilities exert on people, so this market tends to operate mostly in the emotional perspective for customers. In our study, we applied two rigorous methods (ultrasound elasticity measurement and pattern recognition of nipples position) to estimate the effect on the breast state exerted by the bra pads manufactured by BAE International Inc., and we evaluated results in terms of statistical significance.

The presented results demonstrate a clear evidence of positive effect from the bra pads after two-month usage. Subjectively positive experience of wearing the bra pads is a necessary prerequisite, and volunteers from the study group clearly demonstrated it. The results of ultrasound elasticity measurement of the breast state provide objective (statistically significant) evidence that the bust becomes more elastic after bra pads usage. The nipples position pattern also changes, and the quantitative measurements show that the nipples move to higher positions. These results were verified by corresponding measurements for volunteers from the control group, generally increasing the confidence in our results.

The improvement in breast conditions observed in our study can be attributed to a healthier breast state. Both the increasing breast elasticity and the vertical shift of the nipples position can be associated to less severe stages of breast ptosis.<sup>2-8</sup> The observed dynamics in the breast state of volunteers wearing the studied bra pads can thus be related to better blood circulation in breast tissue and improved flow of lymph.<sup>7-8</sup>

Despite good results obtained in our study, they should be considered as rather preliminary. Relatively small number of volunteers in both the study and control groups is a disadvantage of our experimental setup. To gain a more conclusive results, the double-blind approach with four groups, each containing at least 100 patients, is desirable. We hope to extend our study and verify the results under such conditions in the nearest future.

## CONCLUSION

Overall, we may conclude that the continuous usage of bra pads produced by BAE International Inc. leads to increased elasticity of breast and higher positions of nipples. These bra pads can be considered as an effective tool encouraging metabolism by improving the flow of blood circulation and lymph in the breast.

*Funding: No funding sources*

*Conflict of interest: None declared*

*Ethical approval: Not required*

## REFERENCES

1. McGuire KP. Breast Anatomy and Physiology. Aydiner A, İğci A, Soran A. eds. In: Breast Disease: Diagnosis and Pathology. Springer, Cham, 2016.
2. Regnault P. Breast ptosis. Definition and treatment. *Clin Plast Surg.* 1976;3(2):193-203.
3. Rinker B, Veneracion M, Walsh CP. Breast ptosis: causes and cure. *Annals Plastic Surg.* 2010;64(5):579-84.
4. Tairysh GV, Kuzbari R, Rigel S, Todoroff BP, Schneider B, Deutinger M. Normal cutaneous sensibility of the breast. *Plast Reconstr Surg.* 1998;102(3):701-4.
5. Karnes J, Morrison W, Salisbury M, Schaeferle M, Beckham P, Ersek RA. Simultaneous Breast Augmentation and Lift. *Aesth Plast Surg.* 2000;24:148.
6. Turner-Warwick RT. The lymphatics of the breast. *The Brit J Surg.* 1959;46(200):574-82.
7. Halsell JT, Smith JR, Bentlage CR, Park OK, Humphreys JW. Lymphatic drainage of the breast demonstrated by vital dye staining and radiography. *Ann Surg.* 1965;162(2):221-6.
8. Estourgie SH, Nieweg OE, Olmos RA, Rutgers EJ, Kroon BB. Lymphatic drainage patterns from the breast. *Ann Surg.* 2004;239(2):232-7.
9. BAE International Inc Sdn Bhd. Range of products, 2018. Available at: <http://www.mybae.com/knowledge-rangeofproduct.html>. Accessed 19 December 2018.
10. Garra BS. Imaging and estimation of tissue elasticity by ultrasound. *Ultrasound Q.* 2007;23:255-68.
11. Garra BS, Cespedes EI, Ophir J, Spratt SR, Zuurbier RA, Magnant CM, Pennanen MF. Elastography of breast lesions: initial clinical results. *Radiol.* 1997 Jan;202(1):79-86.
12. Regner DM, Hesley GK, Hangiandreou NJ, Morton MJ, Nordland MR, Meixner DD, et al. Breast lesions: evaluation with US strain imaging-clinical experience of multiple observers. *Radiol.* 2006 Feb;238(2):425-37.
13. Zhi H, Ou B, Luo BM, Feng X, Wen YL, Yang HY. Comparison of ultrasound elastography, mammography, and sonography in the diagnosis of solid breast lesions. *J Ultrasound Med.* 2007;26:807Y815.
14. Thomas A, Fischer T, Frey H, Ohlinger R, Grunwald S, Blohmer JU, et al. Real-time elastography-an advanced method of ultrasound: first results in 108 patients with breast lesions. *Ultrasound Obstet Gynecol.* 2006;28:335Y340.
15. Cespedes I, Ophir J, Ponnekanti H, Maklad N. Elastography: elasticity imaging using ultrasound with application to muscle and breast in vivo. *Ultrason Imaging.* 1993;15:73-88.

**Cite this article as:** Kryzhanovskii EV, Yavorsky AB, Choong LK, Bin Abdullah ML. Breast state improvement by using the lymphatic drainage disposable bra pads. *Int J Res Med Sci* 2019;7:795-9.